

# Treatment of Telangiectasia Using a Long Pulsed Nd:YAG Laser with 1.5 mm Spot Size: A Handpiece Evaluation

Jennifer R. Lloyd, D.O.

Lloyd Dermatology and Laser Center, Youngstown, Ohio

## ABSTRACT

The 1064-nm Nd:YAG laser is an effective tool for treating telangiectasia, but there are limitations due to the high fluences required. Large spot sizes are painful, particularly when treating small, superficial vessels with modest absorption. To overcome this, a 1.5-mm hand-

piece was developed for the Apogee Elite Nd:YAG laser platform (Cynosure, Inc., Westford, MA) to deliver higher fluences to superficial lesions with less discomfort to patients. The objective of this study was to evaluate the efficacy of this device for the treatment of telangiectasias. Eleven subjects presenting with facial or leg telangiectasia 0.2 to 1.0 mm in diameter were treated using the Apogee Elite equipped with a 1.5-mm, non-contact handpiece. Vessels were treated by tracing the vessel(s) at 5 to 20-ms pulse duration and a fluences ranging from 300 to 400 J/cm<sup>2</sup>, sufficient to cause either immediate vessel disappearance or coagulation. Subjects were evaluated at intervals of four to six weeks and received one or two additional treatments if necessary. The investigator graded lesions on a percentage scale (Poor= 0–25%, Fair= 26–50%, Good= 51–75%, Excellent= 76–100%) and noted patient perception of pain, improvement, and side effects. Fifty lesions were treated among the 11 patients. All subjects exhibited at least 50% improvement in treated vessels overall, with 41 of 50 treated lesions (82%) resolving after three or fewer treatments. Subjects described discomfort as minimal to moderate. There were few side effects, including transient hyperpigmentation. No subjects had scarring or textural changes. The 1.5-mm handpiece for the Nd:YAG laser provides effective treatment of telangiectasia.

## INTRODUCTION

Laser- and light-based modalities are regularly used for the selective photothermolysis of telangiectasias.<sup>1</sup> The pulsed dye laser (PDL, 585–595 nm), currently the gold standard for facial and smaller leg veins, is limited by shallow depth of penetration and the incidence of

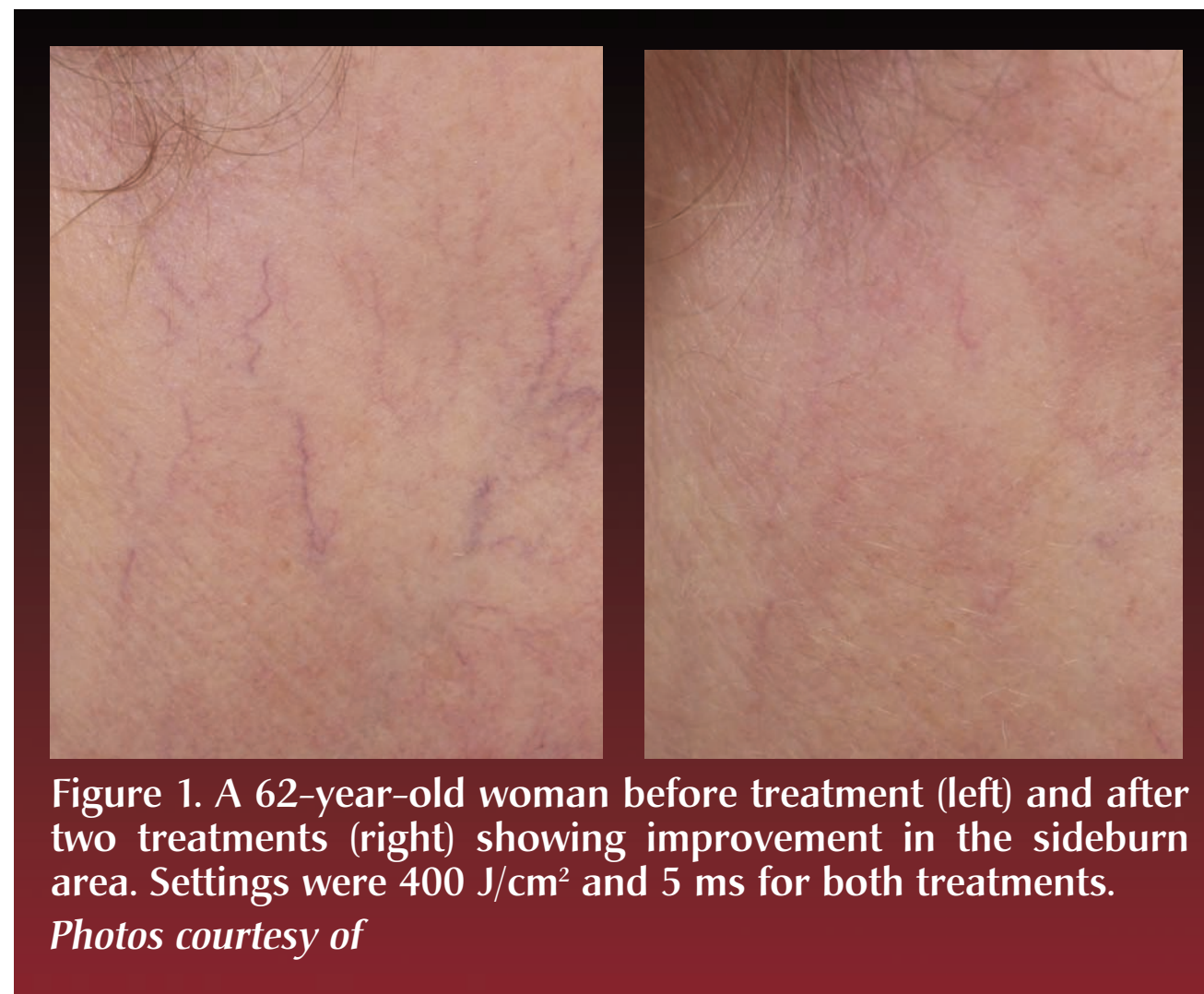

Figure 1. A 62-year-old woman before treatment (left) and after two treatments (right) showing improvement in the sideburn area. Settings were 400 J/cm<sup>2</sup> and 5 ms for both treatments. Photos courtesy of

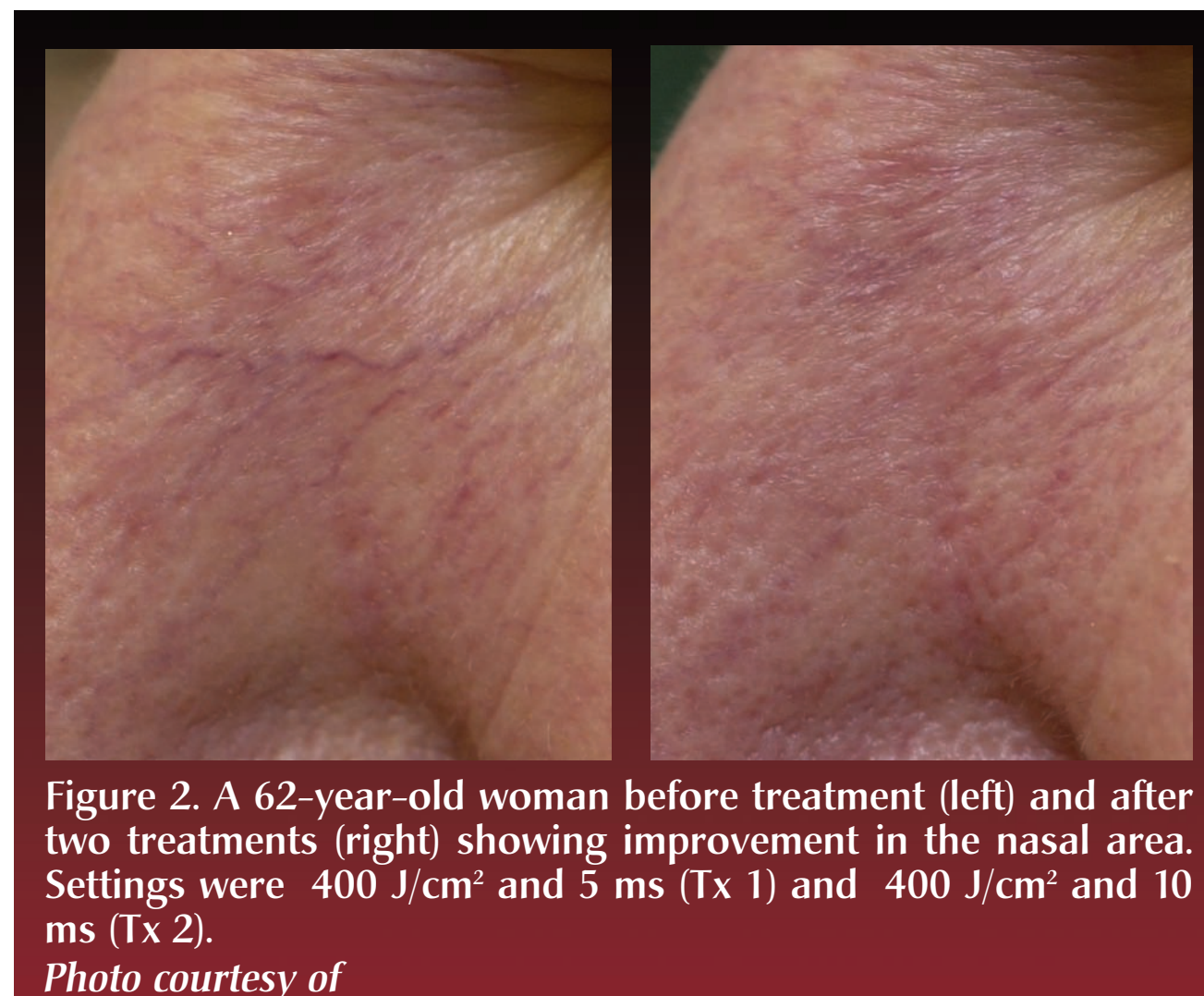


Figure 2. A 62-year-old woman before treatment (left) and after two treatments (right) showing improvement in the nasal area. Settings were 400 J/cm<sup>2</sup> and 5 ms (Tx 1) and 400 J/cm<sup>2</sup> and 10 ms (Tx 2). Photo courtesy of

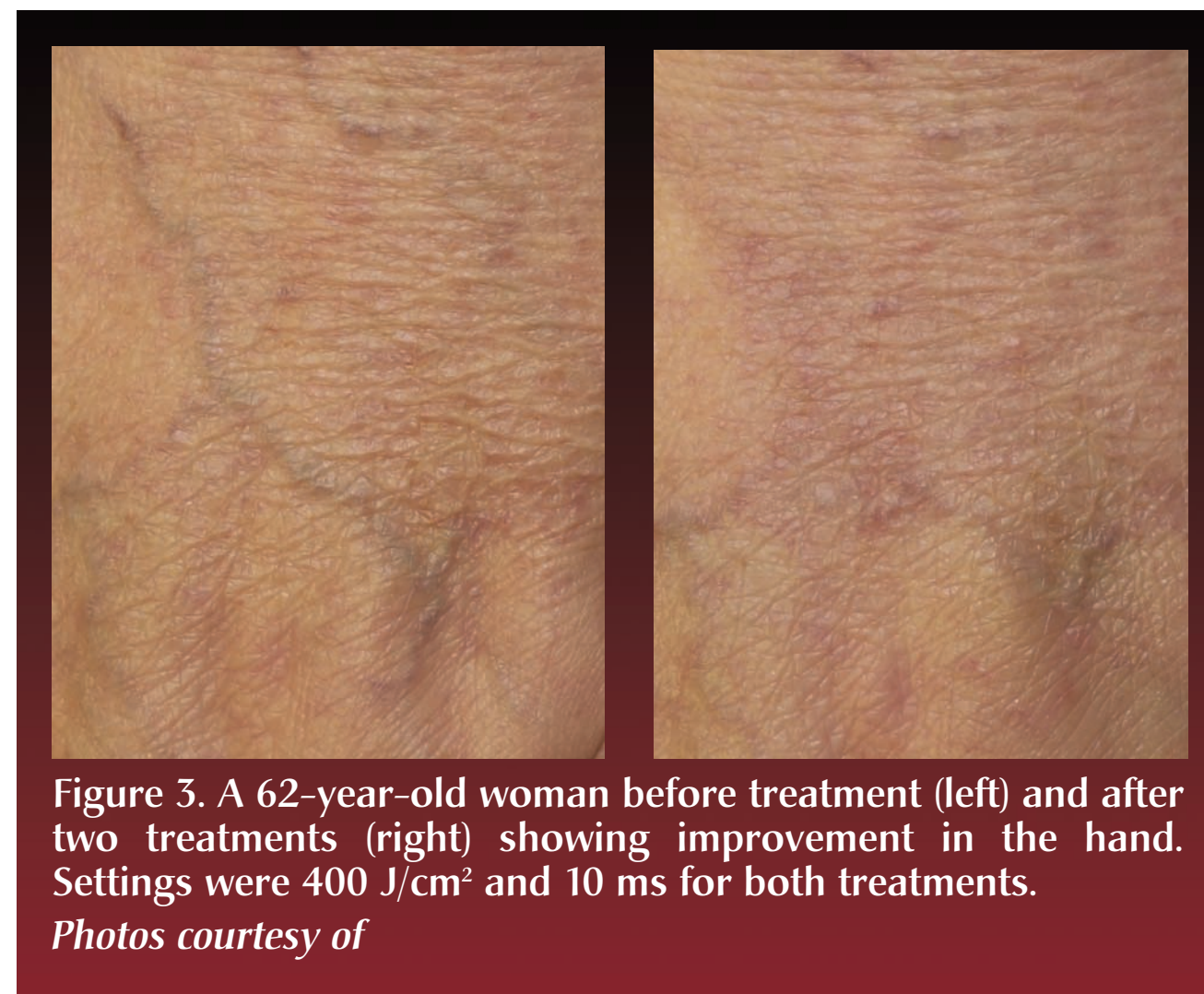

Figure 3. A 62-year-old woman before treatment (left) and after two treatments (right) showing improvement in the hand. Settings were 400 J/cm<sup>2</sup> and 10 ms for both treatments. Photos courtesy of

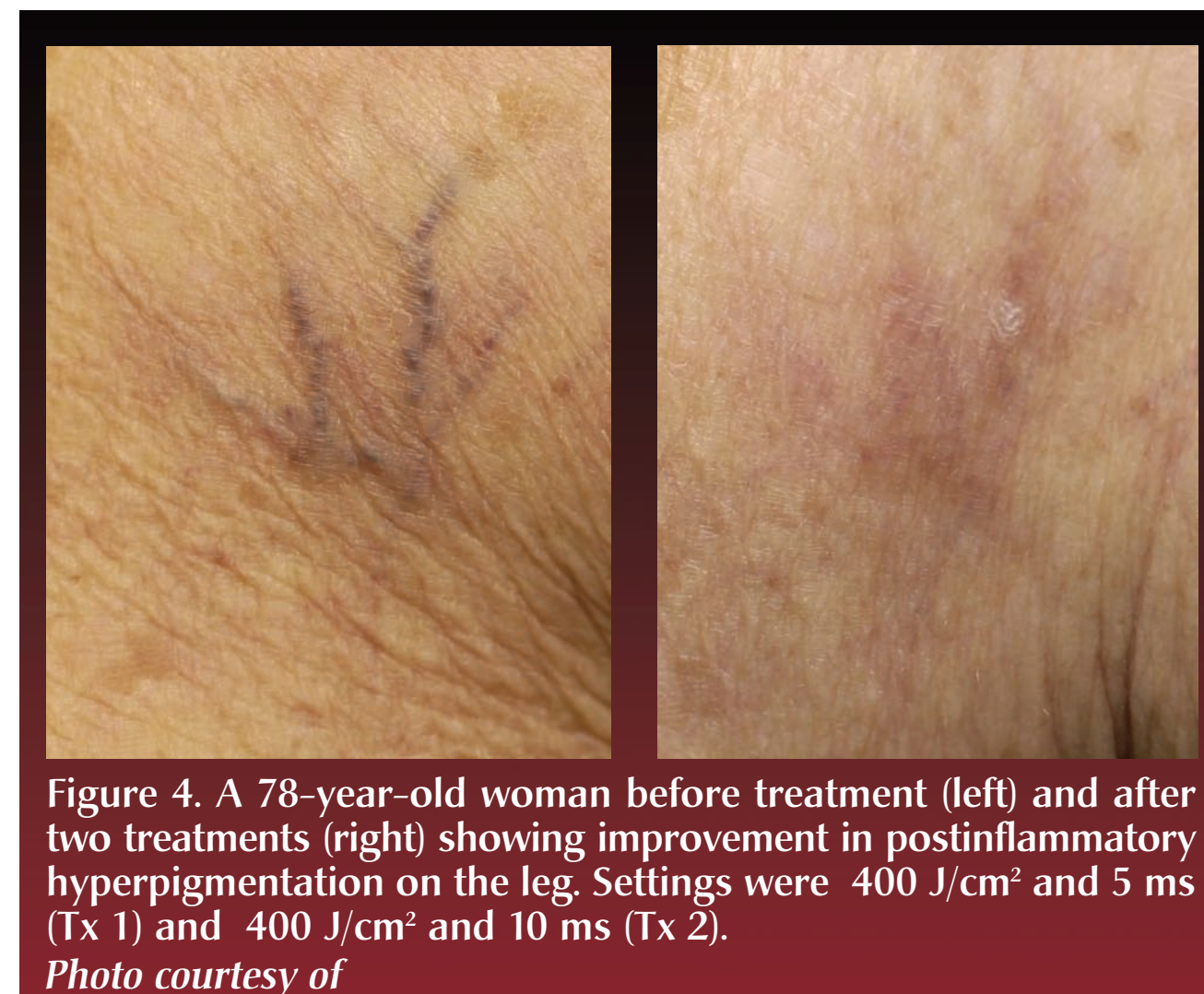


Figure 4. A 78-year-old woman before treatment (left) and after two treatments (right) showing improvement in postinflammatory hyperpigmentation on the leg. Settings were 400 J/cm<sup>2</sup> and 5 ms (Tx 1) and 400 J/cm<sup>2</sup> and 10 ms (Tx 2). Photo courtesy of

transitory purpura. In 2005 Ross and Domankevitz<sup>2</sup> reviewed literature and analyzed the effectiveness of photothermolytic leg vein treatments using Monte Carlo simulations. They theorized that longer wavelengths and pulse durations would be ideal for promoting vessel contraction over intraluminal thrombosis, uniform heating of vessels, and methemoglobin production.

The long-pulsed 1064-nm Nd:YAG laser has been used mostly for larger and deeper veins because the wavelength penetrates more deeply. However, large spot sizes are painful and edema may occur, particularly when treating small, superficial vessels which have modest absorption. Nevertheless the device has been shown in clinical trials to be effective.<sup>3,4</sup>

The Apogee Elite platform (Cynosure, Inc., Westford, MA) features 755-nm Alexandrite and 1064-nm Nd:YAG lasers. The device is FDA cleared for a variety of cosmetic indications including hair removal, vascular and pigmented lesions, and skin rejuvenation. A 1.5-mm handpiece was developed for this device to deliver higher fluences to superficial lesions.

The objective of this study was to evaluate the efficacy of the Apogee Elite 1064-nm Nd:YAG with the 1.5-mm handpiece for the treatment of telangiectasia.

## METHODS

Eleven patients (10 women), presenting with facial or leg telangiectasia 0.2 to 1.0 mm in diameter, were treated using an Apogee Elite Nd:YAG laser equipped with a 1.5-mm, non-contact handpiece. Vessels were treated by tracing the vessel(s) at 5 to 20-ms pulse duration and fluences ranging from 300 to 400 J/cm<sup>2</sup>, sufficient to cause either immediate vessel disappearance or coagulation. Zimmer cooling was used.

Subjects were evaluated at intervals of four to six weeks, with one or two additional treatments performed if

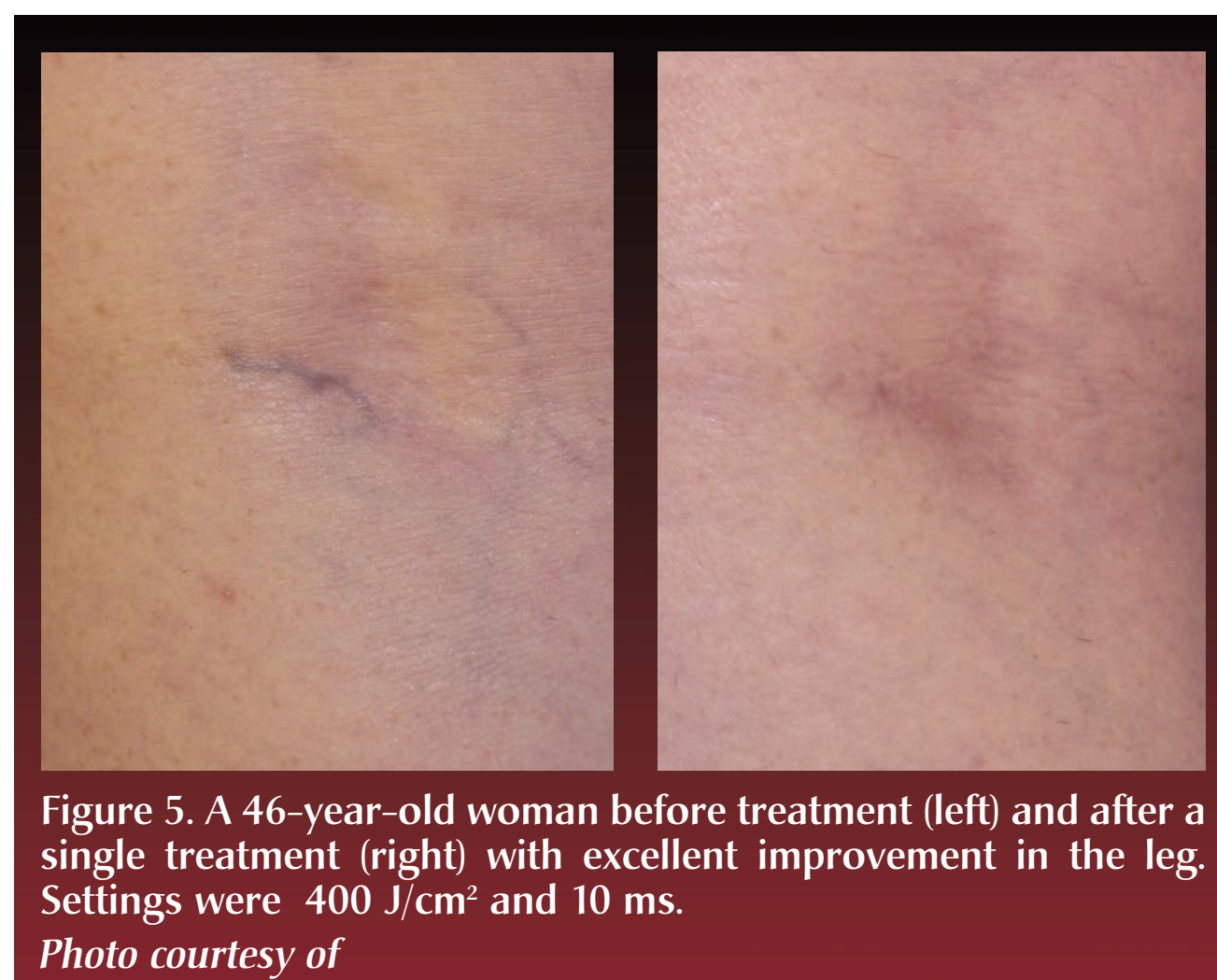


Figure 5. A 46-year-old woman before treatment (left) and after a single treatment (right) with excellent improvement in the leg. Settings were 400 J/cm<sup>2</sup> and 10 ms. Photo courtesy of

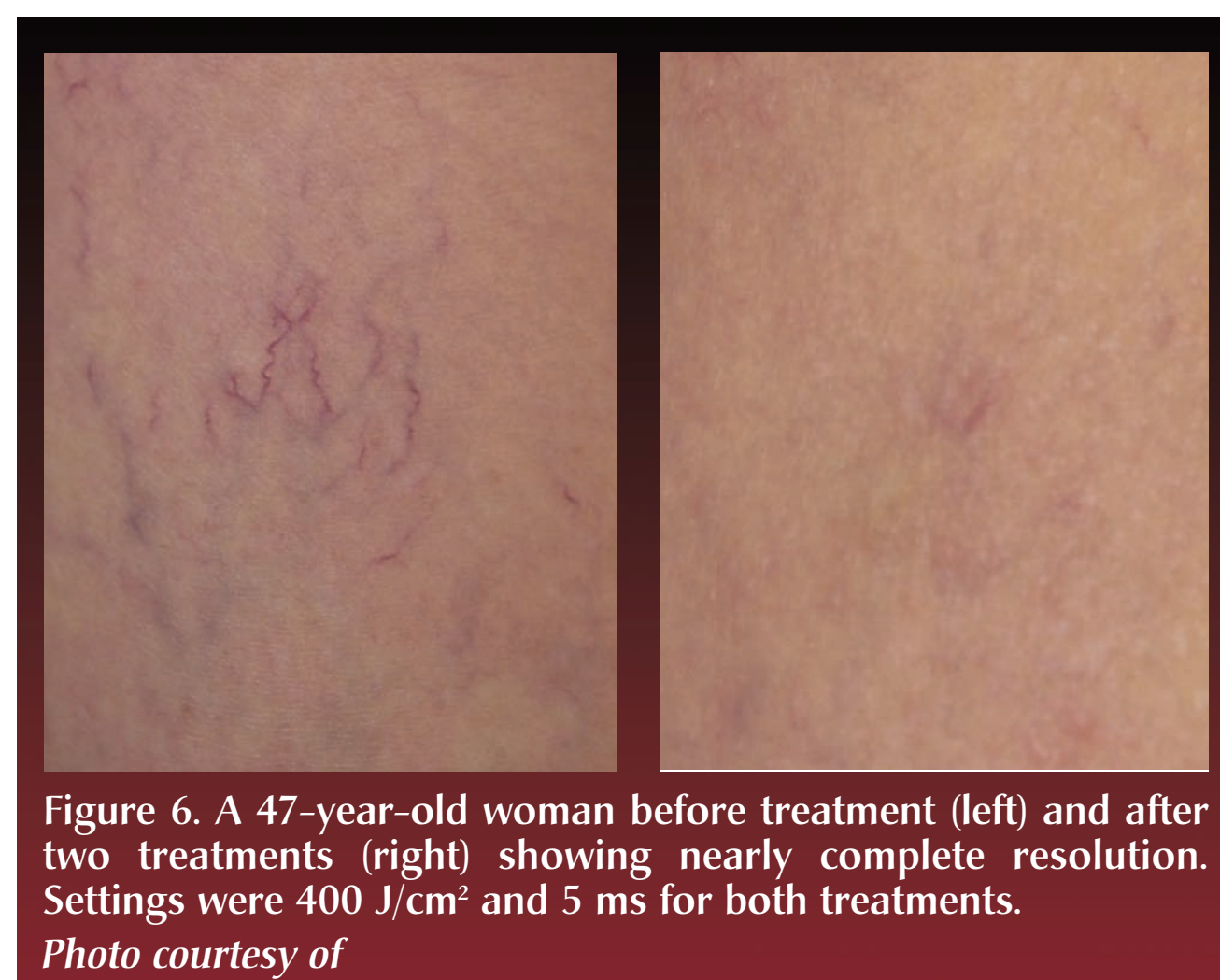


Figure 6. A 47-year-old woman before treatment (left) and after two treatments (right) showing nearly complete resolution. Settings were 400 J/cm<sup>2</sup> and 5 ms for both treatments. Photo courtesy of

## RESULTS

Among the 11 patients, fifty sites were treated. Of those, Excellent clearance was achieved for eight lesions (16%) with the first treatment, 20 lesions (40%) with the second treatment, and 13 lesions (26%) with a third treatment. Of the remaining nine lesions requiring a third treatment

but not graded Excellent, results were judged as Good for three (3), Fair for two (2), and Poor for four (4). Subjects described discomfort as minimal to moderate. There were few side effects, including transient hyperpigmentation. No purpura, scarring, or textural changes were reported or observed.

## DISCUSSION

Recent studies by Bäumer and colleagues<sup>5</sup> and Parlette et al.<sup>6</sup> devoted to finding optimal parameters for Nd:YAG treatment of leg veins, seem to confirm the hypotheses of Ross and Domankevitz.<sup>2</sup> Parlette and

colleagues<sup>6</sup> showed that longer pulse durations may provide gentler heating of vessel and increase the ratio of contraction to thrombosis. The Bäumer study found that smaller spot sizes with moderate fluences (100–400 J/cm<sup>2</sup>) and longer pulse durations (10–100 ms) were most effective and most tolerable to patients.

In the present study, pulse duration was not lengthened but the smaller handpiece size (1.5 mm) allowed the more efficient use of higher fluences (300–400 J/cm<sup>2</sup>). All subjects exhibited at least 50% improvement overall. Forty-one of 50 treated lesions (82%) resolved after three treatments or less. Twenty-eight lesions (56%) resolved after one or two treatments. Poor results (4 lesions, 8%) were observed in veins that were more erythematous in color. Clinical examples are shown in Figures 1–7.

Subjects described discomfort as minimal to moderate. Side effects were minimal and included five cases of post-inflammatory hyperpigmentation (Figure 4), and one case in which the patient developed a small crust which resolved at follow-up without incident.

## CONCLUSION

The 1.5-mm handpiece for the Apogee Elite 1064 nm Nd:YAG laser provides effective treatment of telangiectasia with minimal adverse effects.

## REFERENCES

1. Sadick NS. Laser treatment of leg veins. *Skin Therapy Lett.* 2004;9:6–9.
2. Ross EV, Domankevitz Y. Laser treatment of leg veins: physical mechanisms and theoretical considerations. *Lasers Surg Med.* 2005;36:105–116.
3. Trelles MA, Allones I, Martín-Vázquez MJ, et al. Long-pulse Nd:YAG laser for treatment of leg veins in 40 patients with assessments at 6 and 12 months. *Lasers Surg Med.* 2004;35:68–676.
4. Bevin AA, Parlette EC, Domankevitz Y, Ross EV. Variable-pulse Nd:YAG laser in the treatment of facial telangiectasias. *Dermatol Surg.* 2006;32:7–12.
5. Bäumer W, Ulrich H, Hartl A, et al. Optimal parameters for the treatment of leg veins using Nd:YAG lasers at 1064 nm. *Br J Dermatol.* 2006;155:364–371.
6. Parlette EC, Groff WF, Kinshella MJ, et al. Optimum pulse durations for the treatment of leg telangiectasias with a neodymium YAG laser. *Lasers Surg Med.* 2006;38:98–105.